

## Disc cell therapies: critical issues

Marta Tibiletti · Nevenka Kregar Velikonja ·  
Jill P. G. Urban · Jeremy C. T. Fairbank

Received: 31 December 2012 / Revised: 2 December 2013 / Accepted: 8 January 2014 / Published online: 8 February 2014  
© Springer-Verlag Berlin Heidelberg 2014

### Abstract

**Background** Disc cell therapies, in which cells are injected into the degenerate disc in order to regenerate the matrix and restore function, appear to be an attractive, minimally invasive method of treatment. Interest in this area has stimulated research into disc cell biology in particular. However, other important issues, some of which are discussed here, need to be considered if cell-based therapies are to be brought to the clinic.

**Purpose** Firstly, a question which is barely addressed in the literature, is how to identify patients with ‘degenerative disc disease’ who would benefit from cell therapy. Pain not disc degeneration is the symptom which drives patients to the clinic. Even though there are associations between back pain and disc degeneration, many people with even severely degenerate discs, with herniated discs or with spinal stenosis, are pain-free. It is not possible using currently available techniques to identify whether disc repair

or regeneration would remove symptoms or prevent symptoms from occurring in future. Moreover, the repair process in human discs is very slow (years) because of the low cell density which can be supported nutritionally even in healthy human discs. If repair is necessary for relief of symptoms, questions regarding quality of life and rehabilitation during this long process need consideration.

Also, some serious technical issues remain. Finding appropriate cell sources and scaffolds have received most attention, but these are not the only issues determining the feasibility of the procedure. There are questions regarding the safety of implanting cells by injection through the annulus whether the nutrient supply to the disc is sufficient to support implanted cells and whether, if cells are able to survive, conditions in a degenerate human disc will allow them to repair the damaged tissue.

**Conclusions** If cell therapy for treatment of disc-related disorders is to enter the clinic as a routine treatment, investigations must examine the questions related to patient selection and the feasibility of achieving the desired repair in an acceptable time frame. Few diagnostic tests that examine whether cell therapies are likely to succeed are available at present, but definite exclusion criteria would be evidence of major disc fissures, or disturbance of nutrient pathways as measured by post-contrast MRI.

**Keywords** Disc nutrition · Post-contrast MRI · Cell death · Rehabilitation

---

M. Tibiletti  
IRCCS Istituto Ortopedico Galeazzi, Milan, Italy

*Present Address:*  
M. Tibiletti  
Department of Internal Medicine II-Cardiology,  
University of Ulm, Ulm, Germany

N. Kregar Velikonja  
Educell Ltd., Ljubljana, Slovenija

J. P. G. Urban (✉)  
Department of Physiology, Anatomy and Genetics, Oxford  
University, Oxford, UK  
e-mail: jpgu@physiol.ox.ac.uk

J. C. T. Fairbank  
Nuffield Orthopaedic Centre, Oxford University Hospitals,  
Oxford, UK

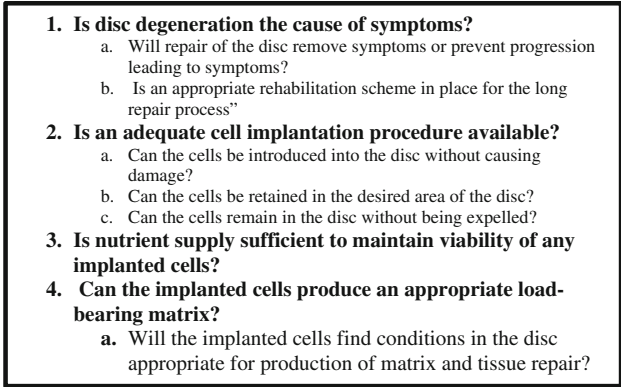
### Introduction

Autologous chondrocyte implantation for repairing articular cartilage defects has been used in the clinic since 1994 [1]. Here, autologous chondrocytes are implanted into a

defect where they produce cartilage matrix and repair the injured cartilage [2]. Following on from the success of cartilage repair, the idea of treating the degenerate disc by a relatively non-invasive injection of autologous cells [3] has captured the imagination of researchers and provided a tremendous stimulus for research into disc biology. For example, the number of papers published on intervertebral disc cells has increased exponentially from fewer than 250 papers in total before 1995 to over 2000 currently (PubMed search). From not knowing whether cells in different regions of the disc were phenotypically distinct or not even 15 years ago [4, 5], the different cell phenotypes populating the nucleus, cartilaginous endplate and annulus have been identified (reviewed [6]), differentiation pathways and progenitors identified [7–9] and specific markers differentiating cells of the nucleus from those of the annulus proposed [10–12]. Methods of culture have advanced from simple three-dimensional culture of primary cells in serum in alginate beads [13] to sophisticated matrices designed to promote differentiation of stem cells towards annulus or nucleus cell phenotypes [14–16]. Other areas of disc biology have also benefited from the interest in repair; knowledge of areas such as annulus structure and cell phenotype [17, 18], of disc-endplate organisation [19, 20], and of the intradiscal environment of degenerate discs (reviewed [21]) has increased substantially over the past decade.

However, in regard to disc repair, though much more is now known of disc tissue and of some of the technical challenges identified even 5 years ago [22, 23] such as identifying disc cell sources appropriate for disc tissue engineering [24–27] and of scaffolds for implanting and supporting such cells [28–32], other issues which have impact on clinical viability of disc repair tissue, such as long turnover times in human discs and nutritional impediments, have been comparatively neglected. Even though clinical implantation of cells into the human disc has been used on a limited number of patients [33–37] and a number of clinical trials are in progress, questions regarding the clinical aims and clinical feasibility of cell therapies for the disc are barely discussed.

Some of the issues which we believe require attention are summarised (Fig. 1). If cell therapy is to become a routine clinical treatment, research into cell therapy for treatment of disc-related disorders must go beyond research into cells and scaffolds and examine questions related to cell therapy practice. These questions are both technical, such as how to implant cells safely into the disc, and how to identify when conditions in a patient's disc are permissive for successful survival and activity of disc cells, but also relate to the important issue of whether a patient's symptoms might benefit from cell therapies. Here we discuss some of these clinical and technical issues relating to

- 
- 1. Is disc degeneration the cause of symptoms?**
    - a. Will repair of the disc remove symptoms or prevent progression leading to symptoms?
    - b. Is an appropriate rehabilitation scheme in place for the long repair process?
  - 2. Is an adequate cell implantation procedure available?**
    - a. Can the cells be introduced into the disc without causing damage?
    - b. Can the cells be retained in the desired area of the disc?
    - c. Can the cells remain in the disc without being expelled?
  - 3. Is nutrient supply sufficient to maintain viability of any implanted cells?**
  - 4. Can the implanted cells produce an appropriate load-bearing matrix?**
    - a. Will the implanted cells find conditions in the disc appropriate for production of matrix and tissue repair?

**Fig. 1** Neglected issues. Some technical and clinical issues which are poorly researched and discussed and yet are important for the clinical success of disc cell therapies

biological therapies for disc repair, concentrating on approaches which seek to repair the disc by implanting cells, but some of the issues raised are also relevant to developing methods that would repair the disc by protein injection or gene therapy.

### Which patients will benefit from cell therapies?

The basic assumption, explicitly stated in most studies on disc repair, is that disc degeneration leads to low back pain which is an enormous clinical problem, and regenerating or repairing the disc will provide symptomatic relief [26, 38, 39]. Disc degeneration itself is, however, universal and in many cases non-symptomatic [40, 41] and there is no means at present of identifying whether anyone with a degenerate disc is likely to develop symptoms [42, 43].

As far as back pain patients are concerned, low back pain and degenerative disc disease are widely used terms, but are not specific; degenerative disc disease, for example, has been used to refer to patients with disc degeneration and non-specific pain, with herniated discs with radiculopathy, with lumbar spinal stenosis and with degenerative spondylolisthesis (reviewed [44]). These patients in general have degenerative or pathological changes to the disc which can be seen on MRI. And while there are studies which indicate that patients with severe disc degeneration are more likely to suffer from back pain [45, 46], it is not evident that the disc is the source of symptoms as severely degenerate discs with pathological features such as disc herniations, annular tears, Modic changes and severe lumbar spinal stenosis are also present in a significant fraction of the symptom-free population [40, 47–50].

There is also no direct evidence that the process of degeneration is responsible for symptoms [42, 51]; the idea that the pain can arise from the disc itself is controversial [52, 53]. Moreover it is not clear whether, in a significant

proportion of patients, regenerating or repairing the disc will provide any relief of pain, the symptom which drives most back pain patients to seek clinical help. Indeed, in many cases, by the time the patient gets to the clinic, epidemiological studies find that 20–35 % of back pain patients suffer from neuropathic pain (reviewed [54]). There is also evidence for augmented pain transmission (central sensitisation) and referred pain in a significant proportion of chronic back pain patients [55]. Thus, for these patients, the Cartesian view of pain, i.e., that a pathological change leads directly to pain and that removal of the pathology will remove the pain, no longer holds [56]. Is disc repair the appropriate treatment for such patients?

Cell therapy has been used on patients to prevent loss of disc height after herniation and to prevent recurrent herniation [34, 57]; interim results found that disc height was not regained after 2 years in comparison with untreated patients though water content was higher [34, 57]. In addition, cell therapies have been used in small pilot studies to alleviate back pain by injecting chondrocytes or stem cells into the disc; in some studies, but not all, patients report some pain benefit and in one case loss of high intensity zones on imaging [33, 35–37, 58]. However, none of these pilot studies have controls. It should be noted that needle injection alone may give pain relief, possibly through a placebo effect, even in cases of chronic back pain [59], so effectiveness of cell-based therapies can only be assessed by well-designed clinical trials. Eight Phase I or Phase II clinical trials on use of cell therapies for treatment of chronic low back pain or of herniated discs are now listed in <http://clinicaltrials.gov/> but no outcomes are yet available.

### Biological repair of human discs: a slow process

Because of its size and avascular nature, the human disc can only support a small number of viable cells; the cell density of the adult nucleus pulposus (NP) is reported to be around 1–5 million cells/ml [60, 61], i.e., <0.5 % tissue volume. Biological repair of human discs would be expected to be slow. Repair in animal models of disc degeneration may thus in general provide an over-optimistic view of success in the human lumbar disc [62], as, apart from other issues concerning the relevance of many of the acute models of degeneration, discs of even large animals, such as pigs, dogs or sheep, are very much smaller than human lumbar discs and support a very much greater cell density [63, 64]. Restoration of disc height has been reported to occur relatively fast in small animals after acutely induced disc degeneration—within 6 weeks in rats [65] and 18 weeks in rabbits [66]. Studies on discs of larger animals such as dogs, pigs and sheep, which are still

considerably smaller than human discs [64, 67] have found that even in young healthy animals with degeneration induced acutely, disc properties were not effectively restored to control values by 3, 6 or even 12 months [24, 68–71].

Repair in human discs, including restoration of disc height, is unlikely to be faster and could be considerably slower than seen in animals—the half life of aggrecan in human discs is 3–6 years and is many decades for fibrillar proteins such as collagen and elastin (reviewed [72]) reflecting the low rate of matrix synthesis and degradation in this tissue. Appropriate clinical rehabilitation regimes, which allow healing without overloading the repair tissue or other structures, have been developed for human knee cartilage [73, 74] This cartilage is much thinner (2–3 mm) and more cellular than the lumbar discs (around 10 million cells/ml [75]), but has still not regained its mechanical properties 12 months after cellular implantation and 3 years is required for the repair tissue to mature [76, 77]. Healing would be considerably slower in the disc which is less cellular and considerably thicker; until it regains stiffness and height, its biomechanical behaviour will not return to normal and other structures such as facet joints will continue to experience inappropriate loads [78]. As far as we can determine the problems arising because of slow healing have not been discussed in relation to cellular repair of discs nor have any rehabilitation regimes been considered in the 8 clinical trials on cell therapy approaches for treating back pain now under way.

### Can cells be safely implanted into the disc?

One advantage put forward for using cell therapies is that they are relatively non-invasive, as cells can be implanted directly into the degraded nucleus by injection. There are, however, factors which need to be considered regarding this technique.

Firstly, after a recent 10-year follow-up study, Carragee et al. [79, 80] reported that, in patients who had undergone discography, painful disc degeneration was accelerated significantly compared to matched controls who had not undergone discography. The discography cohort underwent four times as many lumbar surgeries as the control group over this period. The cause of the damage is not known; it could arise from the contrast medium (CM) used, from needle damage or from pressure damage arising from fluid injection into the disc. While high injection pressures could injure the disc, this has not been discussed directly; only a small volume of fluid can be injected into a normal disc [81] with fluid volume increasing and required injection pressure decreasing as the degree of degeneration increases. Contrast medium could have adverse effects on cell

viability as seen in vitro cell culture tests [82, 83]; however, cells in these tests have been exposed to culture medium for considerably longer durations and higher concentrations than would result from discography in vivo. Of the three proposed modes of damage arising from discography, needle puncture damage of the annulus has been most studied. There are some indications from animal studies that use of very fine needles can obviate damage to the annulus [84, 85]. However, other studies report that needle puncture with a 25G or 26G into the relatively large bovine disc can cause damage to the annulus fibres, changes in disc biomechanical responses and leads to degenerative changes [86, 87]. Until the causes of discography-induced disc damage are identified, implanting cells into the disc via injection through the annulus is potentially risky and risk-benefits have to be considered [88]; therapeutic injection of cells, or indeed any other agent, into the disc for the purpose of reversing the process of disc degeneration could instead actually accelerate it. Some studies are now investigating alternative routes into the disc via the endplate [89], but endplate damage itself can induce disc degeneration [90]. Whether this route is viable in the long term has not yet been proven.

The second issue is whether the implanted cells can be retained in the desired region of the disc. The view of a degenerate nucleus enclosed by an intact annulus which can thus contain any implanted cells does not apply to most adult human discs. Many discs, even at a young age (under 20 years), have small cracks and even major fissures that may not be visible by routine MRI [91–94]. Anterior or posterior radial tears on histological examination, some extending to the disc margins, were found in 47–68 % of young (10–30 years) L4–5 discs, the proportion of discs with such tears increased with age [93]. Virtually all discs examined had concentric tears and many other lesions were reported. There is, thus, a danger that cell suspensions injected into the disc nucleus could be forced into the annulus once the disc is loaded, or indeed out of the disc itself, as seen also in nuclear implants where the annulus is breached [95]. Leakage of cells is potentially harmful, has occurred in animal experiments [96] and could lead to inappropriate osteophyte formation [97]. An intact annulus thus seems a requirement for nucleus cell therapy [98] unless some kind of method of finding and sealing annulus cracks is developed. The requirement of repairing the annulus as well as the nucleus is now becoming recognised [17, 18, 99–102]; however, the necessity for annulus repair moves disc cell therapies away from a simple minimally invasive procedure.

Thus, understanding how to implant cells into the disc safely and maintain them in the required region are areas in urgent need of further study if simple relatively non-invasive disc cell therapies are to be introduced routinely to the clinic.

### Limitations arising from the nutrient supply

A fall in nutrient supply in degenerate discs is one of the main impediments to the success of any form of cell therapy. If the original cells failed to function appropriately, or died because of lack of nutrient supply, the implanted cells will suffer the same fate.

Disc cells, like all others in the body, must have an adequate nutrient supply to survive and function (reviewed [103]); they consume glucose and oxygen and produce metabolic products, particularly lactic acid which acidifies the matrix and must be removed from the tissue to maintain cell viability [104]. The disc is large and avascular. Nutrients are supplied to the cells of the nucleus and inner annulus by capillaries which arise in the vertebral bodies and penetrate the subchondral plate through marrow spaces, terminating in loops at the junction of the subchondral plate and cartilaginous endplate [100]. Nutrients then diffuse through the disc, under concentration gradients governed by the balance between the rate of transport and the rate of cellular demand. Concentrations of glucose and oxygen, which are consumed by the cells, fall with distance from the blood supply and reach low levels in the disc centre while lactic acid concentrations follow a reverse concentration profile [105]. If glucose concentrations fall below 0.2 mM or pH levels fall below pH 6.8, cell survival and activity are compromised [104]. These levels can be disturbed by a fall in the rate of transport. The nutritional pathway from the blood supply to the disc cells is disturbed in degenerate discs through changes such as calcification of the cartilaginous endplate which inhibits diffusion of solutes into the disc [106–108], loss of marrow contacts with the cartilage endplate [109] and atherosclerosis of the vertebral arteries [110]. Disturbances of the nutrient pathway into the discs have long been associated with disc degeneration [109, 111].

Recent developments in MRI have now been able to show this association in vivo. Sequential MR images of the lumbar spine following intravenous injection of a CM are able to follow diffusion of the CM into the disc [112–115]. Post injection, the CM reaches the subchondral plate within 5 min after injection and diffuses into the disc, but is only seen in the central part of the lumbar disc at around 4 h post injection while enhancement peaks in the central part of the (NP) only 6–7 h post injection [114, 116]. In some, but not all studies, peak enhancement is considerably delayed and diminished in intensity in mild or moderately degenerate discs [115, 117] with most hold-up seen in the endplate region. Enhancement into very degenerate discs is rapid, possibly because of endplate breach and vascular ingrowth [114, 115, 117] following from proteoglycan loss [118–120].

This post-contrast method of monitoring transport does not provide direct information on nutrient levels as the transport of CM into the disc is purely diffusive while the gradients of nutrients such as oxygen or glucose are governed by both diffusive transport of these species into the disc and by cellular activity [103]. Therefore, at the moment it is not possible to draw direct conclusions on nutrient levels necessary for cell activity and survival from this methodology. It should be noted that direct measurements of nutrient levels in discs of patients show very varied levels [121], pointing to the complexity of the relationship between the changes in transport in degeneration and cellular activity; such interactions will complicate any assessments. Measurement of both nutrient pathways and viable cell density in a disc would allow assessment of whether nutrient supply is adequate to support the survival of newly implanted cells. The number of viable cells can be assessed *in situ* using two-photon microscope probes introduced through injection needles to measure cell autofluorescence [122]. The potential dangers arising from needle puncture, as noted above, prevent any further development of such measurements at present.

While it is evident that cell therapy cannot succeed without an adequate nutrient supply, the relationship between supply, nutrient concentrations and viable cell density cannot yet be assessed directly. However, the link observed between fall in transport and degeneration [117, 123] suggests that unless the solute transport pathways as shown by post-contrast CM diffusion shows a normal pattern, cell viability or activity is certainly compromised [124]. Such assessment of nutrient supply is essential for determining if treatment by a cell therapy approach is feasible for any particular patient. Patients with abnormal post-contrast diffusion patterns should not be offered cell therapy treatments [124].

### Are conditions in the treated disc permissive of matrix production by implanted cells?

The major aim of cell therapies is to introduce cells which will produce matrix to replace that degraded and lost and, hence, to restore the biomechanical properties and height of the disc. Even if implanted cells survive, disc repair cannot be regarded as successful if these cells are unable to produce sufficient matrix.

The environment of a degenerate disc is inimical to the production and retention of matrix by disc cells. Cells of degenerate discs produce inflammatory cytokines and enzymes which degrade the disc matrix [21, 125–128]; these inflammatory molecules would also tend to degrade matrix produced by implanted cells. Only discs in which this inflammatory process has been dampened down [129],

possibly by gene therapy [130–132], would be appropriate for disc repair. In addition, while variable levels of oxygen, glucose, lactic acid and pH have been reported in degenerate discs, glucose and pH levels tend to be low [121, 133, 134] in agreement with results found in modelling studies [135, 136]. To produce matrix, cells require an extracellular environment with sufficient glucose and where the pH is not acidic (the optimal pH range is pH 7.0–7.2); a fall in pH to below pH 6.8 has disastrous consequences, as rates of matrix production and matrix metabolism fall, but not the rate of matrix degradation [137–140]. Levels of pH in degenerate discs can fall to well below this value [133, 141]. In addition, matrix production is very sensitive to extracellular osmolarity; the osmolarity, directly related to proteoglycan content [142], must be high enough to stimulate matrix production and retention [140, 143, 144]. As one of the first signs of disc degeneration is loss of proteoglycans [145], the low osmolarity found in degenerate discs will reduce rates of matrix production and, indeed, may stimulate expression of proteinases [140].

At present, even if nutrient supply can support implanted cells, there are no non-invasive means of assessing whether the intradiscal environment will support matrix production. However, many needle-based probes exist or are under development which would allow non-destructive assessment of the intradiscal environment. Needle micro-electrodes can be developed to provide assessment of extracellular pH, oxygen and glucose [121, 146]. Needle probes can also assess cell viability [122], as discussed above. A recently developed needle micro-osmometer, based on a microdialysis probe, provides a rapid and sensitive way of measuring osmolarity in disc tissue [147]. If the potential damage arising from needle puncture can be discounted, development of such probes will help identify discs whose nutrient pathways and extracellular environment permit cell survival and matrix production and accumulation.

### Conclusions

Cell therapy for the purpose of treating degenerate disc disease is a very attractive concept. Interest in this approach has stimulated research into the disc and led to a substantial increase in knowledge of disc biology. However, it is difficult to see how cell therapy can be introduced into routine clinical practice in the foreseeable future.

There are still many technical obstacles to be overcome. Injection of cells into the disc is the basis of current cellular repair approaches but needle puncture of the annulus may impose a risk to disc health and the risks need to be weighed against potential benefit. Alternative methods of cell implantation and the realisation that repair of the

annulus may be required in some cases move cell therapy towards a more invasive and less attractive approach. The potential that implanted cells will have to reverse the degeneration process and repair the intervertebral disc in human rather than animal discs remains to be determined. Few diagnostic tests to determine whether cell therapies are likely to succeed in an individual patient are available at present, but definite exclusion criteria would be evidence of major disc fissures or disturbance of nutrient pathways, as measured by post-contrast MRI.

On the clinical side, there is no acceptable diagnostic method at present, of deciding whether an individual patient might benefit from cell therapy. This needs major advances in understanding back pain that have defied serious investigations over the last century. Moreover, it should be realised that human disc regeneration and repair by cell therapies are likely to be very slow and thought should be given to appropriate rehabilitation protocols after implantation.

**Acknowledgments** Funding for this study was received from the European Community's Seventh Framework Programme (FP7, 2007–2013) under grant agreement no. HEALTH-F2-2008-201626.

**Conflict of interest** None.

## References

- Brittberg M, Lindahl A, Nilsson A, Ohlsson C, Isaksson O, Peterson L (1994) Treatment of deep cartilage defects in the knee with autologous chondrocyte transplantation. *N Engl J Med* 331(14):889–895
- Richardson JB, Caterson B, Evans EH, Ashton BA, Roberts S (1999) Repair of human articular cartilage after implantation of autologous chondrocytes (in process citation). *J Bone Joint Surg Br* 81(6):1064–1068
- Alini M, Roughley PJ, Antoniou J, Stoll T, Aebi M (2002) A biological approach to treating disc degeneration: not for today, but maybe for tomorrow. *Eur Spine J* 11(Suppl 2):S215–S220
- Chelberg MK, Banks GM, Geiger DF, Oegema TR Jr (1995) Identification of heterogeneous cell populations in normal human intervertebral disc. *J Anat* 186(Pt 1):43–53
- Horner HA, Roberts S, Bielby RC, Menage J, Evans H, Urban JP (2002) Cells from different regions of the intervertebral disc: effect of culture system on matrix expression and cell phenotype. *Spine* 27(10):1018–1028
- Pattappa G, Li Z, Peroglio M, Wismer N, Alini M, Grad S (2012) Diversity of intervertebral disc cells: phenotype and function. *J Anat* 221(6):480–496
- Sakai D, Nakamura Y, Nakai T, Mishima T, Kato S, Grad S, Alini M, Risbud MV, Chan D, Cheah KS, Yamamura K, Masuda K, Okano H, Ando K, Mochida J (2012) Exhaustion of nucleus pulposus progenitor cells with ageing and degeneration of the intervertebral disc. *Nat Commun* 3:1264
- Risbud MV, Schaefer TP, Shapiro IM (2010) Toward an understanding of the role of notochordal cells in the adult intervertebral disc: from discord to accord. *Dev Dyn* 239(8):2141–2148
- Henriksson H, Thornemo M, Karlsson C, Hagg O, Junevik K, Lindahl A, Brisby H (2009) Identification of cell proliferation zones, progenitor cells and a potential stem cell niche in the intervertebral disc region: a study in four species. *Spine (Phila Pa 1976)* 34(21):2278–2287
- Rodrigues-Pinto R, Richardson SM, Hoyland JA (2013) Identification of novel nucleus pulposus markers: interspecies variations and implications for cell-based therapies for intervertebral disc degeneration. *Bone Joint Res* 2(8):169–178
- Rutges J, Creemers LB, Dhert W, Milz S, Sakai D, Mochida J, Alini M, Grad S (2010) Variations in gene and protein expression in human nucleus pulposus in comparison with annulus fibrosus and cartilage cells: potential associations with aging and degeneration. *Osteoarthritis Cartilage* 18(3):416–423
- Lv F, Leung VY, Huang S, Huang Y, Sun Y, Cheung KM (2013) In search of nucleus pulposus-specific molecular markers. *Rheumatology (Oxford)*. doi:10.1093/rheumatology/ket303
- Maldonado BA, Oegema TR Jr (1992) Initial characterization of the metabolism of intervertebral disc cells encapsulated in microspheres. *J Orthop Res* 10(5):677–690
- Nerurkar NL, Baker BM, Sen S, Wible EE, Elliott DM, Mauck RL (2009) Nanofibrous biologic laminates replicate the form and function of the annulus fibrosus. *Nat Mater* 8(12):986–992
- Frith JE, Cameron AR, Menzies DJ, Ghosh P, Whitehead DL, Gronthos S, Zannettino AC, Cooper-White JJ (2013) An injectable hydrogel incorporating mesenchymal precursor cells and pentosan polysulphate for intervertebral disc regeneration. *Biomaterials* 34(37):9430–9440
- Francisco AT, Mancino RJ, Bowles RD, Brunger JM, Tainter DM, Chen YT, Richardson WJ, Guilak F, Setton LA (2013) Injectable laminin-functionalized hydrogel for nucleus pulposus regeneration. *Biomaterials* 34(30):7381–7388
- Bron JL, Helder MN, Meisel HJ, Van Royen BJ, Smit TH (2009) Repair, regenerative and supportive therapies of the annulus fibrosus: achievements and challenges. *Eur Spine J* 18(3):301–313
- Guterl CC, See EY, Blanquer SB, Pandit A, Ferguson SJ, Benneker LM, Grijpma DW, Sakai D, Eglin D, Alini M, Iatridis JC, Grad S (2013) Challenges and strategies in the repair of ruptured annulus fibrosus. *Eur Cell Mater* 25:1–21
- Nosikova YS, Santerre JP, Grynypas M, Gibson G, Kandel RA (2012) Characterization of the annulus fibrosus-vertebral body interface: identification of new structural features. *J Anat* 221(6):577–589
- Wade KR, Robertson PA, Broom ND (2012) On the extent and nature of nucleus-annulus integration. *Spine (Phila Pa 1976)* 37(21):1826–1833
- Risbud MV, Shapiro IM (2013) Role of cytokines in intervertebral disc degeneration: pain and disc content. *Nat Rev Rheumatol* 10:44–56
- Kandel R, Roberts S, Urban JP (2008) Tissue engineering and the intervertebral disc: the challenges. *Eur Spine J* 17(Suppl):4480–4491
- Paesold G, Nerlich AG, Boos N (2007) Biological treatment strategies for disc degeneration: potentials and shortcomings. *Eur Spine J* 16(4):447–468
- Henriksson H, Hagman M, Horn M, Lindahl A, Brisby H (2011) Investigation of different cell types and gel carriers for cell-based intervertebral disc therapy, in vitro and in vivo studies. *J Tissue Eng Regen, Med*
- Kregar Velikonja N, Frohlich M, Neidlinger-Wilke C, Kletsas D, Urban JPG, Potocar U, Turner S, Roberts S (2012) Cell sources for nucleus pulposus regeneration. *Eur Spine J* [Epub ahead of print]
- Gilbert HT, Hoyland JA, Richardson SM (2013) Stem cell regeneration of degenerated intervertebral discs: current status (update). *Curr Pain Headache Rep* 17(12):377
- Mern DS, Beierfuss A, Thome C, Hegewald AA (2012) Enhancing human nucleus pulposus cells for biological

- treatment approaches of degenerative intervertebral disc diseases: a systematic review. *J Tissue Eng Regen, Med*
28. Pereira DR, Silva-Correia J, Oliveira JM, Reis RL (2013) Hydrogels in acellular and cellular strategies for intervertebral disc regeneration. *J Tissue Eng Regen Med* 7(2):85–98
  29. O'Halloran DM, Pandit AS (2007) Tissue-engineering approach to regenerating the intervertebral disc. *Tissue Eng* 13(8):1927–1954
  30. Collin EC, Grad S, Zeugolis DI, Vinatier CS, Clouet JR, Guicheux JJ, Weiss P, Alini M, Pandit AS (2011) An injectable vehicle for nucleus pulposus cell-based therapy. *Biomaterials* 32(11):2862–2870
  31. Moss IL, Gordon L, Woodhouse KA, Whyne CM, Yee AJM (2011) A novel thiol-modified hyaluronan and elastin-like polypeptide composite material for tissue engineering of the nucleus pulposus of the intervertebral disc. *Spine* 36(13):1022–1029
  32. Richardson SM, Curran JM, Chen R, Vaughan-Thomas A, Hunt JA, Freemont AJ, Hoyland JA (2006) The differentiation of bone marrow mesenchymal stem cells into chondrocyte-like cells on poly-L-lactic acid (PLLA) scaffolds. *Biomaterials* 27(22):4069–4078
  33. Gerber BE, Biedermann M (2006) Nine years follow up after the first autologous human disc regeneration and replantation. 1st meeting of the Bone Research Society (BRS) and the British Orthopaedic Research Society (BORS) on July 5th–6th (2006). Southampton, UK
  34. Meisel HJ, Siodla V, Ganey T, Minkus Y, Hutton WC, Alasevic OJ (2007) Clinical experience in cell-based therapeutics: disc chondrocyte transplantation A treatment for degenerated or damaged intervertebral disc. *Biomol Eng* 24(1):5–21
  35. Haufe SM, Mork AR (2006) Intradiscal injection of hematopoietic stem cells in an attempt to rejuvenate the intervertebral discs. *Stem Cells Dev* 15(1):136–137
  36. Orozco L, Soler R, Morera C, Alberca M, Sanchez A, Garcia-Sancho J (2011) Intervertebral disc repair by autologous mesenchymal bone marrow cells: a pilot study. *Transplantation* 92(7):822–828
  37. Yoshikawa T, Ueda Y, Miyazaki K, Koizumi M, Takakura Y (2010) Disc regeneration therapy using marrow mesenchymal cell transplantation: a report of two case studies. *Spine (Phila Pa 1976)* 35(11):E475–E480
  38. May M (2013) Regenerative medicine: rebuilding the backbone. *Nature* 503(7475):S7–S9
  39. Hudson KD, Alimi M, Grunert P, Hartl R, Bonassar LJ (2013) Recent advances in biological therapies for disc degeneration: tissue engineering of the annulus fibrosus, nucleus pulposus and whole intervertebral discs. *Curr Opin Biotechnol* 24(5):872–879
  40. Boden SD, Davis DO, Dina TS, Patronas NJ, Wiesel SW (1990) Abnormal magnetic-resonance scans of the lumbar spine in asymptomatic subjects. A prospective investigation. *J Bone Joint Surg Am* 72:403–408
  41. Boos N, Semmer N, Elfering A, Schade V, Gal I, Zanetti M, Kissling R, Buchegger N, Hodler J, Main CJ (2000) Natural history of individuals with asymptomatic disc abnormalities in magnetic resonance imaging: predictors of low back pain-related medical consultation and work incapacity. *Spine* 25(12):1484–1492
  42. Kovacs FM, Abreira V, Gervás J, Arana E, Peul WC, Schoene ML, Corbin TP (2012) Overenthusiastic interpretations of a nonetheless promising study. *Transplantation* 93(3):e6–e7
  43. Elfering A, Semmer N, Birkhofer D, Zanetti M, Hodler J, Boos N (2002) Risk factors for lumbar disc degeneration: a 5-year prospective MRI study in asymptomatic individuals. *Spine* 27(2):125–134
  44. Battie MC, Fairbank JCT, Brayda-Bruno M, Varga PP, Lazary A (2013) Disc degeneration related clinical phenotypes. *Eur Spine J* [Epub before print]
  45. Cheung KM, Karppinen J, Chan D, Ho DW, Song YQ, Sham P, Cheah KS, Leong JC, Luk KD (2009) Prevalence and pattern of lumbar magnetic resonance imaging changes in a population study of one thousand forty-three individuals. *Spine (Phila Pa 1976)* 34(9):934–940
  46. Teraguchi M, Yoshimura N, Hashizume H, Muraki S, Yamada H, Minamide A, Oka H, Ishimoto Y, Nagata K, Kagotani R, Takiguchi N, Akune T, Kawaguchi H, Nakamura K, Yoshida M (2013) Prevalence and distribution of intervertebral disc degeneration over the entire spine in a population-based cohort: The Wakayama Spine Study. *Osteoarthritis Cartilage* 22:104–110
  47. Ishimoto Y, Yoshimura N, Muraki S, Yamada H, Nagata K, Hashizume H, Takiguchi N, Minamide A, Oka H, Kawaguchi H, Nakamura K, Akune T, Yoshida M (2013) Associations between radiographic lumbar spinal stenosis and clinical symptoms in the general population: the Wakayama Spine Study. *Osteoarthritis Cartilage* 21(6):783–788
  48. Waris E, Eskelin M, Hermunen H, Kiviluoto O, Paajanen H (2007) Disc degeneration in low back pain: a 17-year follow-up study using magnetic resonance imaging. *Spine (Phila Pa 1976)* 32(6):681–684
  49. Jarvik JG, Deyo RA (2009) Moderate versus mediocre: the reliability of spine MR data interpretations. *Radiology* 250(1):15–17
  50. Wang Y, Videman T, Battie MC (2012) Modic changes: prevalence, distribution patterns, and association with age in white men. *Spine J* 21:2316–2323
  51. Rajasekaran S, Bajaj N, Tubaki V, Kanna RM, Shetty AP (2013) ISSLS prize winner: the anatomy of failure in lumbar disc herniation: an in vivo, multimodal, prospective study of 181 subjects. *Spine (Phila Pa 1976)* 38(17):1491–1500
  52. Malik KM, Cohen SP, Walega DR, Benzon HT (2013) Diagnostic criteria and treatment of discogenic pain: a systematic review of recent clinical literature. *Spine J* 13:1675–1689
  53. Peng BG (2013) Pathophysiology, diagnosis, and treatment of discogenic low back pain. *World J Orthop* 4(2):42–52
  54. Freynhagen R, Baron R (2009) The evaluation of neuropathic components in low back pain. *Curr Pain Headache Rep* 13(3):185–190
  55. Giesecke T, Gracely RH, Grant MA, Nachemson A, Petzke F, Williams DA, Clauw DJ (2004) Evidence of augmented central pain processing in idiopathic chronic low back pain. *Arthritis Rheum* 50(2):613–623
  56. Fairbank J (2002) Clinical importance of the intervertebral disc, or back pain for biochemists. *Biochem Soc Trans* 30:829–831
  57. Hohaus C, Ganey TM, Minkus Y, Meisel HJ (2008) Cell transplantation in lumbar spine disc degeneration disease. *Eur Spine J* 17(Suppl):4492–4503
  58. Coric D, Pettine K, Sumich A, Boltes MO (2013) Prospective study of disc repair with allogeneic chondrocytes presented at the 2012 joint spine section meeting. *J Neurosurg Spine* 18(1):85–95
  59. Pach D, Brinkhaus B, Roll S, Wegscheider K, Icke K, Willich SN, Witt CM (2011) Efficacy of injections with Disci/Rhus toxicodendron compositum for chronic low back pain—a randomized placebo-controlled trial. *PLoS One* 6(11):e26166
  60. Maroudas A, Stockwell RA, Nachemson A, Urban J (1975) Factors involved in the nutrition of the human lumbar intervertebral disc: cellularity and diffusion of glucose in vitro. *J Anat* 120(1):113–130
  61. Liebscher T, Haefeli M, Wuertz K, Nerlich AG, Boos N (2011) Age-related variation in cell density of human lumbar intervertebral disc. *Spine (Phila Pa 1976)* 36(2):153–159
  62. Drazin D, Rosner J, Avalos P, Acosta F (2012) Stem cell therapy for degenerative disc disease. *Adv.Orthop.* doi:10.1155/2012/961052
  63. Holm S, Nachemson A (1983) Cellularity in the intervertebral disc and its relevance to nutrition. In: ISSLS Proceedings

64. Alini M, Eisenstein SM, Ito K, Little C, Kettler AA, Masuda K, Melrose J, Ralphs J, Stokes I, Wilke HJ (2008) Are animal models useful for studying human disc disorders/degeneration? *Eur Spine J* 17(1):2–19
65. Masuda K, Imai Y, Okuma M, Muehleman C, Nakagawa K, Akeda K, Thonar E, Andersson G, An HS (2006) Osteogenic protein-1 injection into a degenerated disc induces the restoration of disc height and structural changes in the rabbit anular puncture model. *Spine (Phila Pa 1976)* 31(7):742–754
66. Sakai D, Mochida J, Iwashina T, Hiyama A, Omi H, Imai M, Nakai T, Ando K, Hotta T (2005) Regenerative effects of transplanting mesenchymal stem cells embedded in atelocollagen to the degenerated intervertebral disc. *Biomaterials* 27:335–345
67. O'Connell GD, Vresilovic EJ, Elliott DM (2007) Comparison of animals used in disc research to human lumbar disc geometry. *Spine (Phila Pa 1976)* 32(3):328–333
68. Thompson JP, Oegema TR, Bradford DS (1991) Stimulation of mature canine intervertebral disc by growth factors. *Spine* 16(3):253–260
69. Reitmaier S, Kreja L, Gruchenberg K, Kanter B, Silva-Correia J, Oliveira JM, Reis RL, Perugini V, Santin M, Ignatius A, Wilke HJ (2013) In vivo biofunctional evaluation of hydrogels for disc regeneration. *Eur Spine J* [Epub ahead of print]
70. Ghosh P, Moore R, Vernon-Roberts B, Goldschlager T, Pascoe D, Zannettino A, Gronthos S, Itescu S (2012) Immunoselected STRO-3 + mesenchymal precursor cells and restoration of the extracellular matrix of degenerate intervertebral discs. *J Neurosurg Spine* 16(5):479–488
71. Ganey T, Hutton WC, Moseley T, Hedrick M, Meisel HJ (2009) Intervertebral disc repair using adipose tissue-derived stem and regenerative cells: experiments in a canine model. *Spine (Phila Pa 1976)* 34(21):2297–2304
72. Sivan SS, Hayes AJ, Wachtel E, Catterson B, Merkher Y, Maroudas A, Brown S, Roberts S (2013) Biochemical composition and turnover of the extracellular matrix of the normal and degenerate intervertebral disc. *Eur Spine J* [Epub ahead of print]
73. Edwards PK, Ackland T, Ebert JR (2013) Clinical rehabilitation guidelines for matrix-induced autologous chondrocyte implantation (MACI) on the tibiofemoral joint. *J Orthop Sports Phys Ther*
74. Davis AM, MacKay C (2013) Osteoarthritis year in review: outcome of rehabilitation. *Osteoarthritis Cartilage* 21(10):1414–1424
75. Stockwell R (1971) The inter-relationship of cell density and cartilage thickness in mammalian articular cartilage. *J Anat* 109:411–421
76. Vasara AI, Nieminen MT, Jurvelin JS, Peterson L, Lindahl A, Kiviranta I (2005) Indentation stiffness of repair tissue after autologous chondrocyte transplantation. *Clin Orthop Relat Res* 433:233–242
77. Hirschmuller A, Baur H, Braun S, Kreuz PC, Sudkamp NP, Niemeyer P (2011) Rehabilitation after autologous chondrocyte implantation for isolated cartilage defects of the knee. *Am J Sports Med* 39(12):2686–2696
78. Swanepoel MW, Adams LM, Smeathers JE (1995) Human lumbar apophyseal joint damage and intervertebral disc degeneration. *Ann Rheum Dis* 54(3):182–188
79. Carragee EJ, Don AS, Hurwitz EL, Cuellar JM, Carrino JA, Herzog R (2009) 2009 ISSLS Prize Winner: does discography cause accelerated progression of degeneration changes in the lumbar disc: a ten-year matched cohort study. *Spine (Phila Pa 1976)* 34:2338–2345
80. Carragee E, Cuellar JM, Hurwitz EL, Carrino JA, Herzog (2011) Does provocative discography cause clinically important injury to the lumbar intervertebral disc? a ten-year matched cohort stud. *Spine J* 11(10):S23–S24
81. Adams MA, Dolan P, Hutton WC (1986) The stages of disc degeneration as revealed by discograms. *J Bone Joint Surg Br* 68(1):36–41
82. Gruber HE, Rhyne AL III, Hansen KJ, Phillips RC, Hoelscher GL, Ingram JA, Norton HJ, Hanley EN Jr (2012) Deleterious effects of discography radioccontrast solution on human annulus cell in vitro: changes in cell viability, proliferation, and apoptosis in exposed cells. *Spine J* 12(4):329–335
83. Chee AV, Ren J, Lenart BA, Chen EY, Zhang Y, An HS (2013) Cytotoxicity of local anesthetics and nonionic contrast agents on bovine intervertebral disc cells cultured in a three-dimensional culture system. *Spine J*. pii:S1529-9430(13)01217-5 [Epub ahead of print]
84. Hsieh AH, Hwang D, Ryan DA, Freeman AK, Kim H (2009) Degenerative anular changes induced by puncture are associated with insufficiency of disc biomechanical function. *Spine (Phila Pa 1976)* 34(10):998–1005
85. Martin JT, Gorth DJ, Beattie EE, Harfe BD, Smith LJ, Elliott DM (2013) Needle puncture injury causes acute and long-term mechanical deficiency in a mouse model of intervertebral disc degeneration. *J Orthop Res* 31(8):1276–1282
86. Michalek AJ, Buckley MR, Bonassar LJ, Cohen I, Iatridis JC (2010) The effects of needle puncture injury on microscale shear strain in the intervertebral disc annulus fibrosus. *Spine J* 10(12):1098–1105
87. Korecki CL, Costi JJ, Iatridis JC (2008) Needle puncture injury affects intervertebral disc mechanics and biology in an organ culture model. *Spine (Phila Pa 1976)* 33(3):235–241
88. Kang JD (2010) Does a needle puncture into the annulus fibrosus cause disc degeneration? *Spine J* 10(12):1106–1107
89. Vadala G, De SF, Bernardini M, Denaro L, D'Avella D, Denaro V (2013) The transpedicular approach for the study of intervertebral disc regeneration strategies: in vivo characterization. *Eur Spine J* (Suppl 6):972–978
90. Adams MA, Roughley PJ (2006) What is intervertebral disc degeneration, and what causes it? *Spine* 31(18):2151–2161
91. Hirsch C, Schajowicz F (1952) Studies on structural changes in the lumbar annulus fibrosus. *Acta Orthop Scand* 22:184–231
92. Videman T, Nurminen M (2004) The occurrence of anular tears and their relation to lifetime back pain history: a cadaveric study using barium sulfate discography. *Spine* 29(23):2668–2676
93. Vernon-Roberts B, Moore RJ, Fraser RD (2007) The natural history of age-related disc degeneration: the pathology and sequelae of tears. *Spine (Phila Pa 1976)* 32(25):2797–2804
94. Fields AJ, Liebenberg EC, Lotz JC (2013) Innervation of pathologies in the lumbar vertebral end plate and intervertebral disc. *Spine J*. pii:S1529-9430(13)01197-2 [Epub ahead of print]
95. Heuer F, Ulrich S, Claes L, Wilke HJ (2008) Biomechanical evaluation of conventional anulus fibrosus closure methods required for nucleus replacement. Laboratory investigation. *J Neurosurg Spine* 9(3):307–313
96. Bertram H, Kroeber M, Wang H, Unklaub F, Guehring T, Carstens C, Richter W (2005) Matrix-assisted cell transfer for intervertebral disc cell therapy. *Biochem Biophys Res Commun* 331(4):1185–1192
97. Vadala G, Sowa G, Hubert M, Gilbertson LG, Denaro V, Kang JD (2011) Mesenchymal stem cells injection in degenerated intervertebral disc: cell leakage may induce osteophyte formation. *J Tissue Eng Regen Med* 6:348–355
98. Omlor GW, Bertram H, Kleinschmidt K, Fischer J, Brohm K, Guehring T, Anton M, Richter W (2010) Methods to monitor distribution and metabolic activity of mesenchymal stem cells following in vivo injection into nucleotomized porcine intervertebral discs. *Eur Spine J* 19(4):601–612
99. Omlor GW, Nerlich AG, Lorenz H, Bruckner T, Richter W, Pfeiffer M, Guhring T (2012) Injection of a polymerized



- hyaluronic acid/collagen hydrogel matrix in an in vivo porcine disc degeneration model. *Eur Spine J* 21(9):1700–1708
100. Driscoll TP, Nakasone RH, Szczesny SE, Elliott DM, Mauck RL (2013) Biaxial mechanics and inter-lamellar shearing of stem-cell seeded electrospun angle-ply laminates for annulus fibrosus tissue engineering. *J Orthop Res* 31(6):864–870
  101. Chang G, Kim HJ, Vunjak-Novakovic G, Kaplan DL, Kandel R (2009) Enhancing annulus fibrosus tissue formation in porous silk scaffolds. *J Biomed Mater Res A* 92:43–51
  102. Hegewald AA, Medved F, Feng D, Tsagogiorgas C, Beierfuss A, Schindler GA, Trunk M, Kaps C, Mern DS, Thome C (2013) Enhancing tissue repair in annulus fibrosus defects of the intervertebral disc: analysis of a bio-integrative annulus implant in an in vivo ovine model. *J Tissue Eng Regen Med*. doi:10.1002/term.1831
  103. Grunhagen T, Shirazi-adl A, Fairbank JC, Urban JP (2011) Intervertebral disk nutrition: a review of factors influencing concentrations of nutrients and metabolites. *Orthop Clin N Am* 42(4):465–477 (vii)
  104. Bibby SR, Urban JP (2004) Effect of nutrient deprivation on the viability of intervertebral disc cells. *Eur Spine J* 13(8):695–701
  105. Holm S, Maroudas A, Urban JP, Selstam G, Nachemson A (1981) Nutrition of the intervertebral disc: solute transport and metabolism. *Connect Tissue Res* 8(2):101–119
  106. Benneker LM, Heini PF, Alini M, Anderson SE, Ito K (2005) 2004 young investigator award winner: vertebral endplate marrow contact channel occlusions and intervertebral disc degeneration. *Spine* 30(2):167–173
  107. Roberts S, Urban JPG, Evans H, Eisenstein SM (1996) Transport properties of the human cartilage endplate in relation to its composition and calcification. *Spine (Phila Pa)* 21:415–420
  108. Hristova GI, Jarzem P, Ouellet JA, Roughley PJ, Epure LM, Antoniou J, Mwale F (2011) Calcification in human intervertebral disc degeneration and scoliosis. *J Orthop Res* 29(12):1888–1895
  109. Nachemson A, Lewin T, Maroudas A, Freeman MAF (1970) In vitro diffusion of dye through the end-plates and annulus fibrosus of human lumbar intervertebral discs. *Acta Orthop Scand* 41:589–607
  110. Kauppila LI (2009) Atherosclerosis and disc degeneration/low-back pain—a systematic review. *Eur J Vasc Endovasc Surg* 37(6):661–670
  111. Kauppila LI, McAlindon T, Evans S, Wilson PW, Kiel D, Felson DT (1997) Disc degeneration/back pain and calcification of the abdominal aorta. A 25-year follow-up study in Framingham. *Spine* 22(14):1642–1647
  112. Nguyen-Minh C, Houghton VM, Papke RA, An H, Censky SC (1998) Measuring diffusion of solutes into intervertebral disks with MR imaging and paramagnetic contrast medium. *Am J Neuroradiol* 19(9):1781–1784
  113. Bydder GM (2002) New approaches to magnetic resonance imaging of intervertebral discs, tendons, ligaments, and menisci. *Spine* 27(12):1264–1268
  114. Rajasekaran S, Babu JN, Arun R, Armstrong BR, Shetty AP, Murugan S (2004) ISSLS prize winner: a study of diffusion in human lumbar discs: a serial magnetic resonance imaging study documenting the influence of the endplate on diffusion in normal and degenerate discs. *Spine* 29(23):2654–2667
  115. Tibiletti M, Galbusera F, Ciavarro C, Brayda-Bruno M (2013) Is the transport of a gadolinium-based contrast agent decreased in a degenerated or aged disc? A post contrast MRI study. *PLoS One* 8(10):e76697
  116. Arun R, Freeman BJ, Scammell BE, McNally DS, Cox E, Gowland P (2009) 2009 ISSLS prize winner: What influence does sustained mechanical load have on diffusion in the human intervertebral disc?: an in vivo study using serial postcontrast magnetic resonance imaging. *Spine (Phila Pa 1976)* 34(21):2324–2337
  117. Rajasekaran S, Naresh-Babu J, Murugan S (2007) Review of postcontrast MRI studies on diffusion of human lumbar discs. *J Magn Reson Imaging* 25(2):410–418
  118. Lama P, Le Maitre CL, Dolan P, Tarlton JF, Harding IJ, Adams MA (2013) Do intervertebral discs degenerate before they herniate, or after? *Bone Joint J* 95-B:1127–1133
  119. Johnson WE, Caterson B, Eisenstein SM, Roberts S (2005) Human intervertebral disc aggrecan inhibits endothelial cell adhesion and cell migration in vitro. *Spine* 30(10):1139–1147
  120. Melrose J, Roberts S, Smith S, Menage J, Ghosh P (2002) Increased nerve and blood vessel ingrowth associated with proteoglycan depletion in an ovine anular lesion model of experimental disc degeneration. *Spine* 27(12):1278–1285
  121. Bartels EM, Fairbank JC, Winlove CP, Urban JP (1998) Oxygen and lactate concentrations measured in vivo in the intervertebral discs of scoliotic and back pain patients. *Spine* 23:1–7
  122. Dittmar R, Potier E, van Zandvoort M, Ito K (2012) Assessment of cell viability in three dimensional scaffolds using cellular autofluorescence. *Tissue Eng C* 18:198–204
  123. Niinimäki J, Korhikoski A, Parviainen O, Haapea M, Kuisma M, Ojala RO, Karppinen J, Korpelainen R, Tervonen O, Nieminen MT (2009) Association of lumbar artery narrowing, degenerative changes in disc and endplate and apparent diffusion in disc on postcontrast enhancement of lumbar intervertebral disc. *MAGMA* 22(2):101–109
  124. Rajasekaran S, Venkatadass K, Naresh BJ, Ganesh K, Shetty AP (2008) Pharmacological enhancement of disc diffusion and differentiation of healthy, ageing and degenerated discs : results from in vivo serial post-contrast MRI studies in 365 human lumbar discs. *Eur Spine J* 17(5):626–643
  125. Roberts S, Caterson B, Menage J, Evans EH, Jaffray DC, Eisenstein SM (2000) Matrix metalloproteinases and aggrecanase: their role in disorders of the human intervertebral disc. *Spine* 25(23):3005–3013
  126. Shamji MF, Setton LA, Jarvis W, So S, Chen J, Jing L, Bullock R, Isaacs RE, Brown C, Richardson WJ (2010) Proinflammatory cytokine expression profile in degenerated and herniated human intervertebral disc tissues. *Arthritis Rheum* 62(7):1974–1982
  127. Seguin CA, Bojarski M, Pilliar RM, Roughley PJ, Kandel RA (2006) Differential regulation of matrix degrading enzymes in a TNF alpha-induced model of nucleus pulposus tissue degeneration. *Matrix Biol* 25(7):409–418
  128. Le Maitre CL, Freemont AJ, Hoyland JA (2005) The role of interleukin-1 in the pathogenesis of human intervertebral disc degeneration. *Arthritis Res Ther* 7(4):R732–R745
  129. Roberts S, Butler RC (2005) Inflammatory mediators as potential therapeutic targets in the spine. *Curr Drug Targets Inflamm Allergy* 4(2):257–266
  130. Le Maitre CL, Hoyland JA, Freemont AJ (2007) Interleukin-1 receptor antagonist delivered directly and by gene therapy inhibits matrix degradation in the intact degenerate human intervertebral disc: an in situ zymographic and gene therapy study. *Arthritis Res Ther* 9(4):R83
  131. Hubert MG, Vadala G, Sowa G, Studer RK, Kang JD (2008) Gene therapy for the treatment of degenerative disk disease. *J Am Acad Orthop Surg* 16(6):312–319
  132. Woods BI, Vo N, Sowa G, Kang JD (2011) Gene therapy for intervertebral disk degeneration. *Orthop Clin N Am* 42(4):563–574 (ix)
  133. Kitano T, Zerwekh JE, Usui Y, Edwards ML, Flicker PL, Mooney V (1993) Biochemical changes associated with the symptomatic human intervertebral disk. *Clin Orthop* 293:372–377
  134. Bibby SR, Fairbank JC, Urban MR, Urban JP (2002) Cell viability in scoliotic discs in relation to disc deformity and nutrient levels. *Spine* 27(20):2220–2228

135. Mokhbi SD, Shirazi-adl A, Urban JP (2009) Investigation of solute concentrations in a 3D model of intervertebral disc. *Eur Spine J* 18(2):254–262
136. Jackson AR, Huang CY, Gu WY (2011) Effect of endplate calcification and mechanical deformation on the distribution of glucose in intervertebral disc: a 3D finite element study. *Comput Methods Biomech Biomed Engin* 14(2):195–204
137. Ohshima H, Urban JPG (1992) Effect of lactate and pH on proteoglycan synthesis rates in the intervertebral disc. *Spine* 17:1079–1082
138. Razaq S, Wilkins RJ, Urban JP (2003) The effect of extracellular pH on matrix turnover by cells of the bovine nucleus pulposus. *Eur Spine J* 12(4):341–349
139. Wuertz K, Godburn K, Iatridis JC (2009) MSC response to pH levels found in degenerating intervertebral discs. *Biochem Biophys Res Commun* 379(4):824–829
140. Neidlinger-Wilke C, Mietsch A, Rinkler C, Wilke HJ, Ignatius A, Urban J (2012) Interactions of environmental conditions and mechanical loads have influence on matrix turnover by nucleus pulposus cells. *J Orthop Res* 30(1):112–121
141. Nachemson A (1969) Intradiscal measurements of pH in patients with lumbar rhizopathies. *Acta Orthop Scand* 40:23–42
142. Urban JPG, McMullin JF (1985) Swelling pressure of the intervertebral disc: influence of proteoglycan and collagen contents. *Biorheology* 22:145–157
143. Ishihara H, Warensjo K, Roberts S, Urban JP (1997) Proteoglycan synthesis in the intervertebral disk nucleus: the role of extracellular osmolality. *Am J Physiol* 272(5 Pt 1):C1499–C1506
144. Wuertz K, Urban JP, Klases J, Ignatius A, Wilke HJ, Claes L, Neidlinger-Wilke C (2007) Influence of extracellular osmolality and mechanical stimulation on gene expression of intervertebral disc cells. *J Orthop Res* 25(11):1513–1522
145. Lyons G, Eisenstein SM, Sweet MB (1981) Biochemical changes in intervertebral disc degeneration. *Biochim Biophys Acta* 673(4):443–453
146. Lowry JP, Miele M, O'Neill RD, Boutelle MG, Fillenz M (1998) An amperometric glucose-oxidase/poly(o-phenylenediamine) biosensor for monitoring brain extracellular glucose: in vivo characterisation in the striatum of freely-moving rats. *J Neurosci Methods* 79(1):65–74
147. Sivan S, Merker HJ, Wachtel E, Urban JPG, Lazary A, Varga PP, Maroudas A (2012) A needle micro-osmometer for determination of proteoglycan concentration in excised nucleus pulposus tissue. *J Orthop Res* 22:1765–1773